

# Circulation

JOURNAL OF THE AMERICAN HEART ASSOCIATION



## **Percutaneous Balloon Aortic Valvuloplasty Revisited: Time for a Renaissance?**

Hidehiko Hara, Wesley R. Pedersen, Elena Ladich, Michael Mooney, Renu Virmani,  
Masato Nakamura, Ted Feldman and Robert S. Schwartz

*Circulation* 2007;115:334-338

DOI: 10.1161/CIRCULATIONAHA.106.657098

Circulation is published by the American Heart Association, 7272 Greenville Avenue, Dallas, TX  
72514

Copyright © 2007 American Heart Association. All rights reserved. Print ISSN: 0009-7322. Online  
ISSN: 1524-4539

The online version of this article, along with updated information and services, is  
located on the World Wide Web at:

<http://circ.ahajournals.org/cgi/content/full/115/12/e334>

Subscriptions: Information about subscribing to *Circulation* is online at  
<http://circ.ahajournals.org/subscriptions/>

Permissions: Permissions & Rights Desk, Lippincott Williams & Wilkins, a division of Wolters  
Kluwer Health, 351 West Camden Street, Baltimore, MD 21202-2436. Phone: 410-528-4050. Fax:  
410-528-8550. E-mail:  
[journalpermissions@lww.com](mailto:journalpermissions@lww.com)

Reprints: Information about reprints can be found online at  
<http://www.lww.com/reprints>

## Percutaneous Balloon Aortic Valvuloplasty Revisited Time for a Renaissance?

Hidehiko Hara, MD; Wesley R. Pedersen, MD; Elena Ladich, MD; Michael Mooney, MD; Renu Virmani, MD; Masato Nakamura, MD; Ted Feldman, MD; Robert S. Schwartz, MD

**C**ase Presentation: A 92-year-old woman presented with progressive heart failure in the setting of known aortic valve stenosis. Despite aggressive medical therapy, she remained in New York Heart Association functional class IV. She lived in an assisted-care facility and wanted to engage in more vigorous daily activities. She did not wish to undergo surgical aortic valve replacement. An echocardiogram showed a left ventricular ejection fraction of 50%. The aortic valve was heavily calcified and severely stenotic, with a mean gradient of 64 mm Hg and an aortic valve area of 0.46 cm<sup>2</sup>.

The patient was offered balloon aortic valvuloplasty, to which she and her family consented. A retrograde approach with a 23-mm balloon was used. A total of 3 inflations were carried out across the aortic valve during simultaneous rapid ventricular pacing at 220 bpm. The postvalvuloplasty mean gradient was reduced to 28 mm Hg, and the aortic valve area increased to 0.98 cm<sup>2</sup>. She was seen in the clinic 6 months later with stable functional class II symptoms and re-

mained quite satisfied with her improved lifestyle.

Calcific aortic stenosis (AS) is the most frequent expression of valvular heart disease in the Western world, with increasing prevalence expected as the population ages. Three percent of all adults  $\geq 75$  years of age have moderate or severe AS, and it is the leading indication for valve replacement in Europe and the United States. Surgical aortic valve replacement is the preferred treatment strategy for patients of all age groups, although it has limitations in the octogenarian and nonagenarian populations. Open heart approaches are limited by higher perioperative risk, prolonged recovery, and poor quality of life after surgery.<sup>1</sup> The surgical 30-day mortality rate for the nonagenarian population is  $\approx 17\%$  in 1 contemporary series, with 40% mortality by 13 months.<sup>2</sup>

Less invasive percutaneous options are needed for poor-surgical-risk patients with severe AS. Balloon aortic valvuloplasty (BAV) is currently the only approved catheter-based option for nonsurgical patients, a procedure that has been underused in those pa-

tients relegated to medical therapy alone. This procedure fell from favor secondary to perceived procedural complexity, suboptimal initial results, and high restenosis rates in the 6 to 12 months after the procedure.<sup>3</sup> As the number of very elderly with this disease increases, especially those in whom surgical options are not available, an effective and less invasive treatment of severe AS is essential. About one third of patients with severe AS are not referred for valve replacement surgery because of the risks perceived by both patients and physicians. The use of BAV for palliation of symptoms has been undervalued in this difficult-to-treat patient group.

### Pathophysiology of AS

A normal aortic valve leaflet consists of 3 layers (Figure 1). AS is considered a form of atherosclerosis, and early valve lesions show subendothelial cellular and extracellular lipid accumulation on the aortic side of leaflets, much like what occurs in atherosclerotic disease. Such lesions include oxidized low-density lipoprotein, lipoprotein(a), inflammatory cells, and calcification.

From the Minneapolis Heart Institute Foundation, Abbott Northwestern Hospital, Minneapolis, Minn (H.H., W.R.P., M.M., R.S.S.); CV Path, International Registry of Pathology, Gaithersburg, Md (E.L., R.V.); Division of Cardiovascular Medicine, Toho University, Ohashi Medical Center, Tokyo, Japan (M.N.); and Evanston Northwestern Hospital, Evanston, Ill (T.F.).

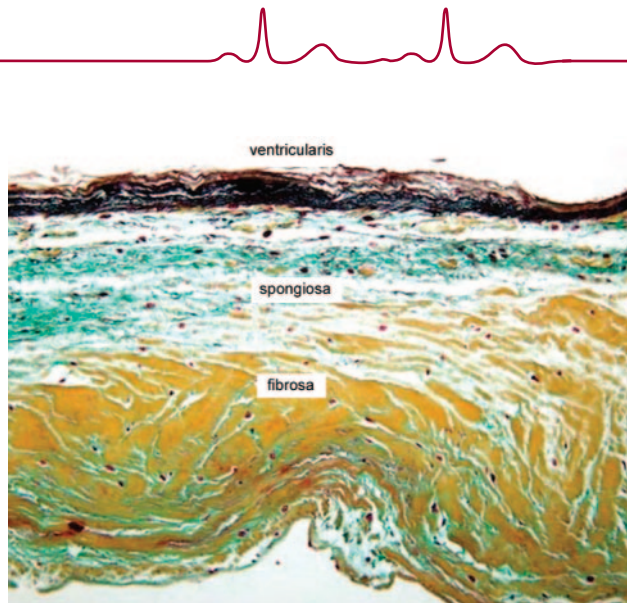
Correspondence to Robert S. Schwartz, MD, Minneapolis Heart Institute and Minneapolis Heart Institute Foundation, 920 E 28th St, Ste 620, Minneapolis, MN 55407. E-mail [rss@rsschwartz.com](mailto:rss@rsschwartz.com)

(*Circulation*. 2007;115:e334-e338.)

© 2007 American Heart Association, Inc.

*Circulation* is available at <http://www.circulationaha.org>

DOI: 10.1161/CIRCULATIONAHA.106.657098



**Figure 1.** Layered architecture of normal aortic valve leaflet. The ventricular surface has a black-staining elastic layer (ventricularis). A dense collagenous layer (fibrosa) extends toward the aortic surface. The spongiosa is a loose connective tissue layer rich in proteoglycan.

Severely stenotic leaflets have prominent calcification with lipocalcific changes on the aortic side of leaflet.

Active bone formation is an important component of AS.<sup>4</sup> Early lesion initiation results from endothelial layer disruption caused by mechanical

forces such as shear stress and abnormal blood flow patterns. Lipid accumulation, especially with low-density lipoprotein, begins within the leaflet subendothelial layer and is modified by inflammatory and cytokine interactions. The angiotensin-converting en-

zyme cascade also works locally within the aortic leaflet, causing fibroblasts within the fibrosa layer to differentiate into myofibroblasts wherein the angiotensin I receptor is highly expressed. The myofibroblast cell plays a central role in the process because it is believed to differentiate into an osteoblast-like cell phenotype, which in turn promotes deposition of calcified nodules and bone formation.

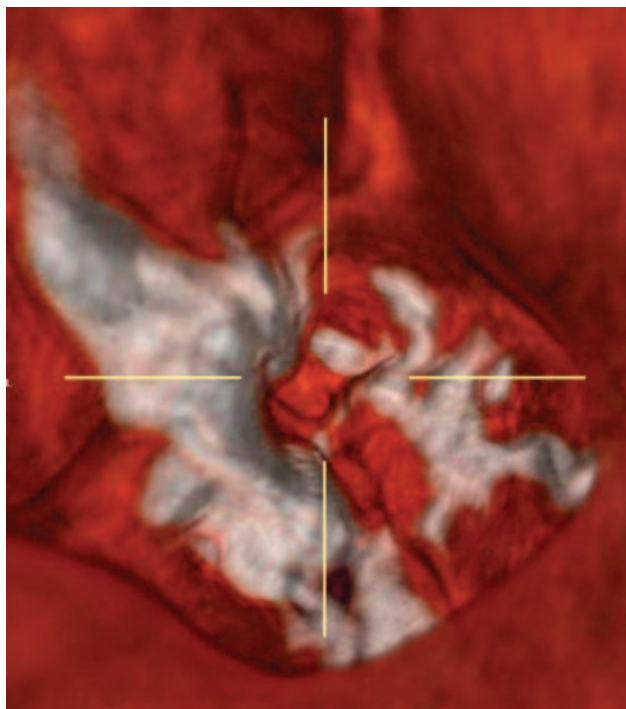
### Novel Relevant Pathophysiological Insights From In Vivo 3-Dimensional Imaging

Investigations into the relationship between aortic valve calcium and stenotic area by multislice computed tomography show causal mechanisms.<sup>5</sup> Three-dimensional images reveal important information about leaflet calcification and stenosis severity. Figure 2 supports the observation that extravalvular calcification affects leaflet motility, especially when calcium accumulates in the outflow tract and aortic root. Calcification within these locations may severely restrict leaflet motion and enhance stenosis severity.

### Current Therapy and Results

#### Surgical Replacement

Surgical valve replacement should be considered the treatment of choice for severe AS patients regardless of age. Moderate-to-severe AS occurs in 5% of individuals 75 to 86 years of age, and critical AS is seen in >5% of those >85 years of age.<sup>6</sup> Increasing numbers of octogenarians and nonagenarians are presenting with severe AS for consideration of open heart surgery, and physicians are increasingly confronted by the growing dilemma of finding suitable therapy for elderly patients who are often poorly suited for traditional valve replacement surgery. Surgical success rates for these very elderly patients are improving but remain suboptimal. In-hospital death and stroke rates may be as high as 8.5% and 8%, respectively.<sup>1</sup> Mean duration of postoperative hospital stay in most



**Figure 2.** Three-dimensional volume-rendering images reveal that extravalvular calcification of the valve leaflet, especially toward the left ventricle outflow tract, may restrict the motion of the leaflet, which can be worked as a hinge point.

reports is >2 weeks for very elderly patients, with most being discharged to nursing care facilities. Furthermore, many elderly patients refuse surgery despite favorable outcomes, making less invasive, percutaneous therapy an attractive option for enhancing their quality of life. Moreover, disability often results from aortic valve replacement surgery in elderly patients. Less specific cognitive deficits also are common. More than half of all octogenarians are discharged to rehabilitation facilities, even after minimally invasive approaches are used, and >20% are rehospitalized within 1 month.<sup>7</sup>

### Aortic Valvuloplasty as a Forgotten Therapy

Percutaneous aortic valvuloplasty was developed as a nonsurgical option in the 1980s. It was found to have a role in managing unstable and critically ill patients such as those in cardiogenic shock or refractory heart failure. A mean age of  $78 \pm 9$  years was reported in the National Heart, Lung and Blood Institute (NHLBI) valvuloplasty registry and was typical of "younger" patients who underwent BAV 2 decades ago. A consistent limitation for this therapy among younger patients with greater longevity was the high restenosis rate and the need for reintervention. BAV was thus found to be of limited utility for many of these patients who were acceptable candidates for aortic valve replacement.

High complication rates and in-hospital mortality also were reported early in the experience, suggesting complications in 25% of patients (167 of 672) within 24 hours of the procedure and documenting death in 3% (17 of 672).<sup>8</sup> The most common complication was transfusion in 20%, related predominantly to vascular entry site complications (136 of 672; Table 1).<sup>8</sup> Cumulative cardiovascular mortality before discharge was 8% in the NHLBI registry. Restenosis and recurrent hospitalization were common, although survivors reported fewer symptoms over the subsequent 1.5 years.<sup>3</sup> Most patients who are very elderly

**TABLE 1. Complications During or Within 24 Hours After Valvuloplasty Procedure**

Complication	n (%)
Death	17 (3)
Patients with any severe complication	167 (25)
Type of complication	
Hemodynamic	
Prolonged hypotension	51 (8)
CPR required	26 (4)
Pulmonary edema	19 (3)
Cardiac tamponade	10 (1)
IABP use	11 (2)
Acute valvular insufficiency	
Aortic	6 (1)
Mitral	1 (0.1)
Cardiogenic shock	15 (2)
Neurological	
Vasovagal reaction	36 (5)
Seizure	15 (2)
Transient loss of consciousness	4 (0.6)
Focal neurological event	13 (2)
Respiratory	
Intubation	28 (4)
Arrhythmia	
Treatment required	64 (10)
Persistent bundle-branch block	34 (5)
AV block requiring pacing	30 (4)
VF or VT requiring countershock	18 (3)
Vascular	
Significant hematoma	44 (7)
Vascular surgery performed	33 (5)
Systemic embolic event	11 (2)
Transfusion required	136 (20)
Ischemic	
Prolonged angina	9 (1)
Acute myocardial infarction	10 (1)
Other severe complications	
Pulmonary artery perforation	1 (0.1)
Acute tubular necrosis	1 (0.1)

CPR indicates cardiopulmonary resuscitation; IABP, intra-aortic balloon pump; AV, atrioventricular; VF, ventricular fibrillation; and VT, ventricular tachycardia. N=672.

often are considered too frail to undergo BAV or aortic valve replacement. In a comparable patient population without AS, median expected survival was only 2 years, regardless of valve condition.<sup>9</sup> The most impor-

**TABLE 2. Patients in Whom Percutaneous Balloon Aortic Valvuloplasty Should Be Considered**

Patients with symptomatic AS and any of the following:

Bridge to surgical AVR in hemodynamically unstable patients

Increased perioperative risk, STS risk score >15%

Anticipated survival of <3 y

Age in the late 80s or 90s and prefer BAV over open thoracotomy

Severe comorbidities such as porcelain aorta, severe lung disease, and others for which the CV surgeon prefers not to operate

Severe and/or disabling neuromuscular or arthritic conditions that would limit the ability to undergo postoperative rehabilitation

AVR indicates aortic valve replacement; STS, Society of Thoracic Surgeons; and CV, cardiovascular.

tant predictor of event-free survival after BAV was left ventricular function at baseline (ejection fraction >25%).<sup>10</sup> BAV may be a forgotten therapy, but analysis suggests that it offers benefits to the very elderly high-risk patient who is looking for significant symptomatic improvement that is not available from medical therapy alone. Table 2 shows informal guidelines currently used by our institutions to select patients suitable for BAV.

### Mechanisms of Dilation

The effects of BAV on the aortic valve are poorly understood, but several mechanisms are likely. The most common effect is intraleaflet fractures within calcified nodular deposits. These represent leaflet hinge points and may increase flexibility within the calcified aortic root to improve valve opening. Other possible mechanisms include scattered leaflet microfractures, cleavage planes along collagenized stroma, and uncommon separation of fused leaflets. Enhanced compliance of the rigidly calcified adjacent aortic root, which may follow BAV, may further contribute to greater leaflet flexibility. That no single mechanism has been proved suggests insufficient data and leaves unanswered the

question of novel strategies for valvular dilation.

### Silver Linings to a Dark Cloud

Several technical and procedural improvements are now available for BAV that did not exist 20 years ago when Cribier first described the procedure.<sup>10a</sup> Rapid ventricular pacing (200 to 220 bpm) now arrests mechanical systole to preserve balloon stability across the aortic valve during inflation. The Inoue balloon (typically used for mitral valvuloplasty) improves immediate post-BAV aortic valve area compared with conventional and retrograde BAV.<sup>11</sup> Enhanced valve opening may be achieved through leaflet hyperextension into the broader aortic root diameter. The “dumbbell”-shaped Inoue balloon locks on the aortic valve and can accomplish leaflet hyperextension with a rounded distal end without overstretching the valve annulus engaged by the narrower neck.<sup>12</sup> Furthermore, inflation–deflation times are faster, and given the required antegrade transvenous approach, peripheral arterial complications are less likely. Immediate post-BAV valve area is affected by pre-BAV severity and correlated with improved hemodynamic long-term follow-up.

Investigations suggest that repeat balloon valvuloplasty in AS patients across multiple age groups (59 to 104 years) may improve 3-year survival rates over a single dilatation.<sup>13</sup> Repeat BAV can be performed without additional complications. Most patients have symptomatic relief for a year or more. The value of symptomatic palliation in this population cannot be understated. Minimizing the need for repeated hospitalizations for heart failure has a large impact on quality of life for these 80- to 95-year-old patients. Misconceptions often include a higher-than-reported rate of complications such as perioperative stroke, post-BAV aortic insufficiency, and myocardial perforation. In a series of 86 patients  $\geq 80$  years of age, no myocardial perforations occurred, and only 1 pa-

tient developed severe aortic regurgitation.<sup>14</sup> Only 1 of 86 patients suffered stroke, and the overall periprocedural mortality was 2.2%. Data from our group show successful simultaneous coronary stenting with BAV in 11 patients (mean age, 87 years; range, 79 to 99 years) between July 2003 and May 2006 without complications or in-hospital mortality (unpublished data, Minneapolis Heart Institute BAV registry). These data represent a favorable trend that is important given the incidence of severe coronary artery disease in these patients of 50%.

### Valvular Restenosis and Prevention

#### External Beam Radiation

The Radiation Following Percutaneous Balloon Aortic Valvuloplasty to Prevent Restenosis (RADAR) pilot trial suggests that external beam radiation may significantly reduce restenosis. Restenosis in the RADAR pilot study was 20% at 12 months in a population with an average age of 89 years, suggesting utility in elderly patients.<sup>15</sup> This surprising benefit may occur through the previously demonstrated ability of external beam radiation therapy to limit the formation of scar tissue and heterotopic ossification previously reported in restenotic aortic valves.

#### Potential for Transcatheter Implantation and Antirestenotic Drug Therapy

Percutaneous heart valve implantation with stent-based valves has been performed in initial feasibility studies in inoperable patients with severe AS. Immediate and early clinical improvement has been achieved in small patient numbers with this technique. BAV will play a crucial role in preparing the stenotic aortic valve for the prosthetic implantation. Further device improvements and long-term follow-up are required in these novel implantation devices before premarket approval is obtained.

Antirestenotic drug therapy after BAV has not been attempted, but preclinical studies to prevent calcification

have been investigated in surgical settings. Because drug-eluting stents have replaced brachytherapy in the management of coronary artery disease and restenosis, local drug elution into dilated aortic valves may be possible, in theory, to prevent restenosis after BAV or work primarily to stimulate bone regression.

### Conclusions and Summary

Aortic valvuloplasty strategies should be reevaluated, given the enhanced knowledge of vascular and valvular biology that permits targeted therapy to prevent restenosis and to delay or reverse valve mineralization. The increasing numbers of poor surgical candidates in the expanding very elderly population mandate less invasive methods such as BAV to improve quality of life. The time has arrived for balloon aortic valvuloplasty to be revisited, and a resurgence of this procedure is becoming possible through improved knowledge and refined transcatheter device developments.

The patient presented in this Clinician Update needs to be followed up regularly to monitor for evidence of restenosis. If restenosis of the aortic valve occurs and is clinically significant, a repeat BAV can be performed.

### Disclosures

None.

### References

- Kolh P, Kerzmann A, Lahaye L, Gerard P, Limet R. Cardiac surgery in octogenarians: peri-operative outcome and long-term results. *Eur Heart J*. 2001;22:1235–1243.
- Edwards MB, Taylor KM. Outcomes in nonagenarians after heart valve replacement operation. *Ann Thorac Surg*. 2003;75:830–834.
- Otto CM, Mickel MC, Kennedy JW, Alderman EL, Bashore TM, Block PC, Brinker JA, Diver D, Ferguson J, Holmes DR Jr. Three-year outcome after balloon aortic valvuloplasty: insights into prognosis of valvular aortic stenosis. *Circulation*. 1994;89:642–650.
- Feldman T, Glagov S, Carroll JD. Restenosis following successful balloon valvuloplasty: bone formation in aortic valve leaflets. *Cathet Cardiovasc Diagn*. 1993;29:1–7.
- Koos R, Mahnken AH, Sinha AM, Wildberger JE, Hoffmann R, Kuhl HP. Aortic



- valve calcification as a marker for aortic stenosis severity: assessment on 16-MDCT. *AJR Am J Roentgenol.* 2004;183:1813–1818.
6. Lindroos M, Kupari M, Heikkilä J, Tilvis R. Prevalence of aortic valve abnormalities in the elderly: an echocardiographic study of a random population sample. *J Am Coll Cardiol.* 1993;21:1220–1225.
  7. Goodney PP, Stukel TA, Lucas FL, Finlayson EV, Birkmeyer JD. Hospital volume, length of stay, and readmission rates in high-risk surgery. *Ann Surg.* 2003;238:161–167.
  8. Percutaneous balloon aortic valvuloplasty: acute and 30-day follow-up results in 674 patients from the NHLBI Balloon Valvuloplasty Registry. *Circulation.* 1991;84:2383–2397.
  9. Horstkotte D, Loogen F. The natural history of aortic valve stenosis. *Eur Heart J.* 1988;9(suppl E):57–64.
  10. Kuntz RE, Tosteson AN, Berman AD, Goldman L, Gordon PC, Leonard BM, McKay RG, Diver DJ, Safian RD. Predictors of event-free survival after balloon aortic valvuloplasty. *N Engl J Med.* 1991;325:17–23.
  - 10a. Cribier A, Savin T, Saoudi N, Rocha P, Berland J, Letac B. Percutaneous transluminal valvuloplasty of acquired aortic stenosis in elderly patients: an alternative to valve replacement? *Lancet.* 1986;1:63–67.
  11. Eisenhauer AC, Hadjipetrou P, Piemonte TC. Balloon aortic valvuloplasty revisited: the role of the Inoue balloon and transseptal antegrade approach. *Catheter Cardiovasc Interv.* 2000;50:484–491.
  12. Feldman T. Transseptal antegrade access for aortic valvuloplasty. *Catheter Cardiovasc Interv.* 2000;50:492–494.
  13. Agarwal A, Kini AS, Attanti S, Lee PC, Ashtiani R, Steinheimer AM, Moreno PR, Sharma SK. Results of repeat balloon valvuloplasty for treatment of aortic stenosis in patients aged 59 to 104 years. *Am J Cardiol.* 2005;95:43–47.
  14. Eltchaninoff H, Cribier A, Tron C, Anselme F, Koning R, Soyer R, Letac B. Balloon aortic valvuloplasty in elderly patients at high risk for surgery, or inoperable: immediate and mid-term results. *Eur Heart J.* 1995;16:1079–1084.
  15. Pedersen WR, Van Tassel RA, Pierce TA, Pence DM, Monyak DJ, Kim TH, Harris KM, Knickelbine T, Lesser JR, Madison JD, Mooney MR, Goldenberg IF, Longe TF, Poulouse AK, Graham KJ, Nelson RR, Pritzker MR, Pagan-Carlo LA, Boisjolie CR, Zenovich AG, Schwartz RS. Radiation following percutaneous balloon aortic valvuloplasty to prevent restenosis (RADAR pilot trial). *Catheter Cardiovasc Interv.* 2006;68:183–192.