
Proceedings of the TCT: Balloon Aortic Valvuloplasty Appropriate for Elderly Valve Patients

TED FELDMAN, M.D.

From Evanston Northwestern Healthcare, Cardiac Catheterization Laboratory, Evanston Hospital, Evanston, Illinois

Balloon aortic valvuloplasty (BAV) has been a highly successful therapy for children and young adults with aortic valve stenosis, resulting in both symptomatic improvement and durable increases in the aortic valve area. Despite enthusiasm for BAV in older adult patients with aortic valve stenosis in the mid-1980s, the therapy has had disappointing medium- and long-term outcomes. Survival of patients with aortic valve stenosis does not increase with BAV, and restenosis occurs in the vast majority of patients within 6–24 months after therapy. Despite these limitations, most patients are symptomatically improved for a year or more. BAV remains an effective palliative therapy for selected patients. (J Intervent Cardiol 2006;19:276–279)

Introduction

Balloon aortic valvuloplasty (BAV) is not recommended by many cardiologists as an alternative for poor surgical candidates, because it does not prolong survival in this patient group. Palliation for debilitating symptoms is highly effective with BAV among patients with severe aortic valve stenosis and comorbid surgical risk factors. While hospital mortality for valve replacement in octogenarian patients may range from 10–20%, 1-year survival may still be only 50–60%. Most of these elderly patients are discharged to rehabilitation facilities rather than to home, and quality of life after surgical valve replacement may be poor. This article will examine the role of BAV in high-risk surgical patients as an alternative that may provide symptom relief with minimal recovery time and acceptable risk.

Balloon Aortic Valvuloplasty Improves Quality of Life, Avoids Surgical Risks

Despite a lack of impact on long-term mortality, balloon aortic valvuloplasty (BAV) remains a palliative therapy for many patients who are otherwise poor

candidates for valve replacement surgery. The goal of therapy in older adults with aortic valve stenosis may often be pure symptom relief.^{1–6} Octogenarian and nonagenarian patients with multiple comorbidities are often hospitalized repeatedly for congestive heart failure and are debilitated to the point that their activities of daily living are highly compromised. Significant quality-of-life improvements to these patients consist of enough clinical improvement to avoid frequent hospitalizations, engage more fully in activities of daily living, and experience relief of symptoms. For this group of patients, the potential for improved symptoms with minimal procedural morbidity and a short hospital stay is highly attractive.

It is not widely appreciated that aortic valve surgery in this group of patients is complicated by more than an increased in-hospital or 30-day surgical risk.^{7–12} While the upper decile of patients at high risk for aortic valve replacement (AVR) surgery may have hospital mortality in the range of 15–18%, which is quite acceptable in this group, their 1-year survival is not substantially different than either untreated patients or BAV patients, with 1-year mortality as high as 40–50%.

Furthermore, for this group of patients, quality of life is the major reason for intervention of any kind. In my own conversations with elderly patients regarding the management for aortic valve disease, they are relatively unconcerned about procedure mortality and

Address for reprints: Ted Feldman, M.D., Evanston Hospital, 2650 Ridge Ave., Evanston, Illinois 60201. e-mail: tfeldman@enh.org

highly concerned about the potential for stroke or prolonged disability during the recovery period. More than 50% of octogenarian and nonagenarian patients treated with AVR are discharged to nursing home facilities and may spend anywhere from 1 to 4 months undergoing rehabilitation.¹¹ Readmission to the hospital within 30 days of operation occurs in almost 20% of Medicare patients after AVR surgery.¹² For patients with a limited life span, this represents a significant loss of quality of life. In addition, the perioperative stroke rate in this group ranges between 5% and 15%, compared to 1% or less with BAV. Neurocognitive deficits may diminish the functional capacity of an additional substantial proportion of patients as well.¹³⁻¹⁴

Octogenarians, Ambulatory Elderly with Comorbid Conditions Best Candidates

Accordingly, BAV may represent an attractive alternative therapy for many of these older patients. Certainly, patients in the octogenarian decade who are good candidates for AVR should have this therapy; however, many of these patients have already undergone a prior sternotomy or have other comorbidities, including chronic lung disease, renal failure, chronic anemia, porcelain aorta, or multiple comorbidities. For these high-risk patients, BAV may offer excellent palliation for 1–2 years, with a hospital mortality of 5–8%, and a length of stay of 1–2 days.¹⁵ Length of stay for octogenarian patients after aortic valve surgery averages 2 weeks.¹² Most patients return to full activity immediately after discharge. Another variable is patient preference. It is common for older patients, especially those who have had a prior sternotomy, to want to avoid a major operation.

The best candidates for BAV are the ambulatory elderly. The prototypic patient is >80 years old with some comorbidity for valve surgery, but not yet hospital-bound. Patients who have been hospitalized for days or weeks, who are “stuck” on pressors, or are septic are less likely to tolerate a BAV procedure.

Retrograde, Antegrade Techniques Both Improved since the 1980s

The techniques for performing aortic valvuloplasty include the conventional retrograde approach and the more recently utilized antegrade transseptal ap-

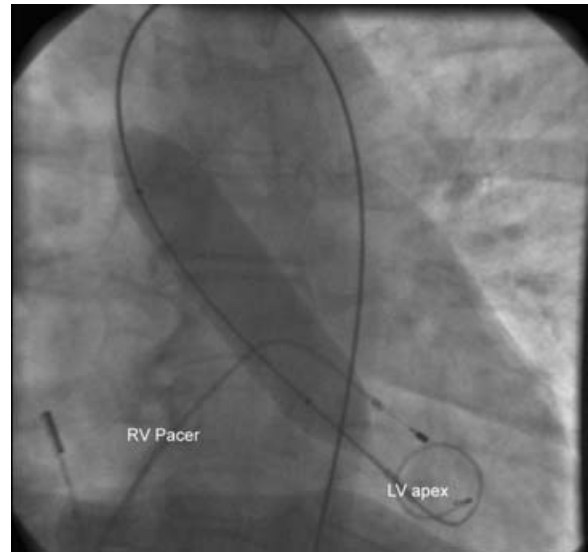


Figure 1. Retrograde valvuloplasty using a 22-mm diameter conventional balloon.

proach.¹⁶⁻¹⁸ Both techniques have improved considerably since they were introduced in the 1980s. The acute results of balloon dilatation are substantially better than they have been in the past, and the quality of the acute result has been demonstrated to correlate with the durability to some degree.

Retrograde valvuloplasty requires an 11 or 12 F arterial sheath. This is limiting in a remarkably small proportion of this patient population, since survival into this age group is often accompanied by surprisingly less atherosclerotic and peripheral vascular disease. After placement of a large sheath, the valve is crossed retrograde and a balloon catheter ranging from 20 mm to 24 mm in diameter is passed retrograde across the valve and inflated to relieve the stenosis.

Recently, rapid right ventricular pacing has been introduced as a method to diminish balloon “watermelon seeding” during balloon inflations (see Fig. 1). Without this adjunct, ventricular systole, especially in patients with preserved left ventricular systolic function, ejects the balloon during inflation attempts in the stenotic aortic valve. Burst pacing at between 200 and 220 beats/min effectively reduces cardiac output sufficiently to allow the balloon to be positioned for inflations in a stable manner. Shorter balloons can thus be used, thereby diminishing the time of the inflation–deflation cycle. The entire procedure is facilitated, and better acute results can be obtained.

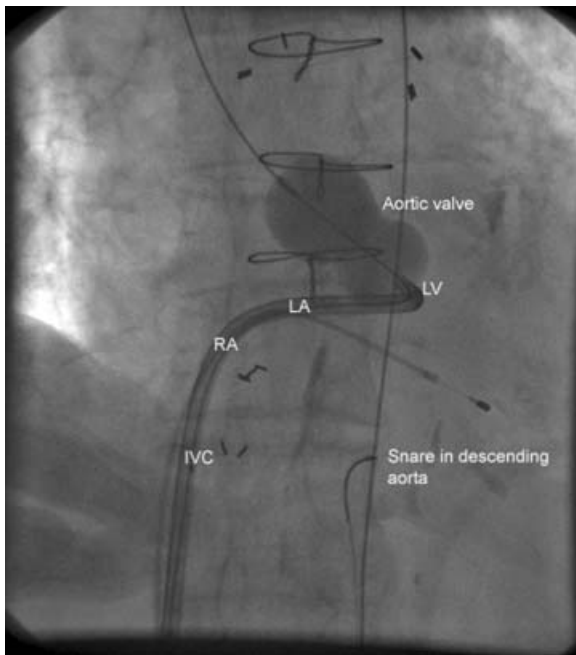


Figure 2. Antegrade balloon aortic valvuloplasty using a 26-mm diameter Inoue balloon catheter.

Preclosure Aids Puncture Management

The use of suture preclosure has diminished the challenges in managing the large arterial puncture.^{19–20} Using a single 10 F Perclose device or two 6 F Closer-S devices, immediate hemostasis can be obtained in the vast majority of patients. This has been demonstrated to virtually eliminate the need for periprocedural blood transfusions. Using manual compression, the rate of transfusion has been 25%. In one series, transfusion was completely eliminated with the use of suture preclosure. In addition, the length of stay was diminished from over 5 days in patients treated with manual compression to an average of 2.2 days for patients treated using the suture preclosure approach.

More recently, improved acute results from antegrade BAV have been described.¹⁷ This approach eliminates the need for large-caliber arterial puncture. A 12 or 14 F sheath can be placed in the right femoral vein to allow transeptal access and antegrade passage of a wire loop through the circulation, followed by balloon placement. Venous preclosure may be used as well, which similarly simplifies the management of the large venous puncture.

Antegrade valvuloplasty may be performed with a conventional balloon or with an Inoue balloon (see

Fig. 2). The valve areas achieved with the Inoue device are significantly greater than with a conventional balloon, due at least in part to the larger size balloon that can be used with the Inoue approach and possibly also to a more advantageous geometry of the Inoue balloon in relation to the valve and sinuses of Valsalva. The antegrade approach is more complex technically, but has the advantages of eliminating the need for a large arterial puncture, allowing more stable positioning of the balloon in the valve, and facilitating the delivery of a larger balloon into the valve orifice. The Inoue balloon in particular has a very rapid inflation and deflation cycle, with very little hemodynamic instability during the procedure.

Most patients are palliated for 1–2 years after BAV. For many, this means that they avoid the repeated hospitalizations for congestive heart failure that are the most common current indication for this procedure.

Neutron Beam X-ray, Percutaneous Methods Hold Promise

In an attempt to improve the durability of BAV results, Pederson has recently described focused neutron beam X-ray therapy for BAV patients.²¹ Among patients who achieved a good initial result, a number have reached the 1-year postprocedure mark with a completely preserved postprocedure aortic valve area. This is a remarkable improvement in the results of this procedure, which has been plagued by an almost uniform occurrence of restenosis in the vast majority of patients.

A future role of BAV will be influenced by the development of methods for percutaneous AVR. Some patients may undergo BAV as a bridge or as therapy for shock, in preparation for percutaneous valve replacement. Current approaches for percutaneous valve replacement require BAV as predilatation for the placement of either self-expanding or balloon-expandable stent-mounted bioprosthetic valve prostheses. Thus, the importance of BAV-associated techniques may increase in the near future.

It has been observed that statin therapy may diminish the progression of aortic stenosis. This has been seen in a number of observational studies, but to date, a single randomized trial is negative.²² Unless a medical therapy for the prevention of aortic stenosis is developed, the number of patients in need of valve therapy will grow substantially as the population ages. Accordingly, it remains unclear whether the incidence of senile

calcific aortic stenosis will remain stable or decline in the next few decades.

In current practice, BAV is underutilized for the palliation of severe aortic stenosis in patients who are poor candidates for AVR surgery. Advanced age, porcelain aorta, prior sternotomy, low body mass index, and multiple organ system comorbidities remain important indications for the use of this therapy in octogenarian and nonagenarian patients.

References

1. Bonow RO, Carabello B, de Leon AC Jr, et al. Guidelines for the management of patients with valvular heart disease: Executive summary. A report of the American College of Cardiology/American Heart Association Task Force on Practice Guidelines (Committee on Management of Patients with Valvular Heart Disease). *Circulation* 1998;98:1949–1984.
2. Feldman T, Chiu YC, Carroll JD. Catheter balloon dilatation for discrete subaortic stenosis in the adult. *Am J Cardiol* 1987;60:403–405.
3. Feldman T, Glagov S, Carroll JD. Restenosis following successful balloon valvuloplasty; bone formation in aortic valve leaflets. *Cathet Cardiovasc Diagn* 1993;29:1–7.
4. Otto CM, Mickel MC, Kennedy JW, et al. Three year outcome after balloon aortic valvuloplasty. Insights into prognosis of valvular aortic stenosis. *Circulation* 1994;89:642–650.
5. Lieberman EB, Bashore TM, Hermiller JB, et al. Balloon aortic valvuloplasty in adults: Failure of procedure to improve long-term survival. *J Am Coll Cardiol* 1995;26:1522–1528.
6. O’Keefe JH Jr, Vlietstra RE, Bailey KR, et al. Natural history of candidates for balloon aortic valvuloplasty. *Mayo Clin Proc* 1987;62:986–991.
7. Levinson JR, Akins CW, Buckley MJ, et al. Octogenarians with aortic stenosis. Outcome after aortic valve replacement. *Circulation* 1989;80:149–156.
8. Kolh P, Kerzmann A, Lahaye L, et al. Cardiac surgery in octogenarians; peri-operative outcome and long-term results. *Eur Heart J* 2001;22:1235–1243.
9. Burr LH, Jamieson WR, Munro AI, et al. Porcine bioprostheses in the elderly: Clinical performance by age groups and valve positions. *Ann Thorac Surg* 1995;60:S264–S269.
10. Goodney PP, Stukel TA, Lucas FL, et al. Hospital volume, length of stay, and readmission rates in high-risk surgery. *Ann Surg* 2003;238:161–167.
11. Sharony R, Grossi EA, Saunders PC, et al. Minimally invasive aortic valve surgery in the elderly: A case-control study. *Circulation* 2003;108:II43–II47.
12. Sundt TM, Bailey MS, Moon MR, et al. Quality of life after aortic valve replacement at the age of >80 years. *Circulation* 2000;102:III70–III74.
13. Zimpfer D, Czerny M, Kilo J, et al. Cognitive deficit after aortic valve replacement. *Ann Thorac Surg* 2002;74:407–412.
14. Newman MF, Kirchner JL, Phillips-Bute B, et al. Neurological Outcome Research Group and the Cardiothoracic Anesthesiology Research Endeavors Investigators. Longitudinal assessment of neurocognitive function after coronary-artery bypass surgery. *N Engl J Med* 2001;344:395–402.
15. Agarwal A, Kini AS, Attanti S, et al. Results of repeat balloon valvuloplasty for treatment of aortic stenosis in patients aged 59 to 104 years. *Am J Cardiol* 2005;95:43–47.
16. Feldman T, Chiu YC, Carroll JD. Single balloon aortic valvuloplasty: Increased valve areas with improved technique. *J Invasive Cardiol* 1989;1:295–300.
17. Sakata Y, Sayed Y, Salinger MH, et al. Percutaneous balloon aortic valvuloplasty: Antegrade transseptal versus conventional retrograde transarterial approach. *Cathet Cardiovasc Interv* 2005;64:314–321.
18. Feldman T. Transseptal antegrade access for aortic valvuloplasty. *Cathet Cardiovasc Interv* 2000;50:492–494.
19. Solomon LW, Fusman B, Jolly N, et al. Percutaneous suture closure for management of large French size arterial puncture in aortic valvuloplasty. *J Invasive Cardiol* 2001;13:592–596.
20. Feldman T. Percutaneous suture closure for management of large French size arterial and venous puncture. *J Interv Cardiol* 2000;13:237–242.
21. Pederson WR, Pence D, Knickelbine T, et al. Radiation following percutaneous balloon aortic valvuloplasty to prevent restenosis (RADAR Pilot). *Circulation* 2004;100:440.
22. Cowell SJ, Newby DE, Prescott RJ, et al. Scottish Aortic Stenosis and Lipid Lowering Trial, Impact on Regression (SALTIRE) Investigators. A randomized trial of intensive lipid-lowering therapy in calcific aortic stenosis. *N Engl J Med* 2005;352:2389–2397.