

## VALVULAR HEART DISEASE

---

### *Proceedings of TCT: Current Status of Catheter-Based Mitral Valve Repair Therapies*

TED FELDMAN, M.D.

*From the Northwestern University School of Medicine, Cardiac Catheterization Laboratory, Evanston Hospital, Evanston, Illinois*

---

*A variety of advances have recently facilitated development of methods to treat mitral regurgitation using catheter techniques via the percutaneous route. These include placing devices into the coronary sinus to support the mitral annulus and direct percutaneous leaflet repair. These approaches are already attractive for use in older patients and will hopefully make treatments available to many with no current options. (J Interven Cardiol 2006;19:396–400)*

---

#### Introduction

The majority of patients with valvular heart disease in the United States have regurgitant lesions. As many as 250,000 of these have mitral regurgitation. In addition, more than half of the 4 million plus Americans with dilated cardiomyopathy have some degree of functional mitral regurgitation. Over 50,000 mitral valve surgical procedures are performed annually, most for mitral regurgitation. Many of the patients with both degenerative and functional mitral regurgitation are poor candidates for surgery, most often due to associated poor left ventricular function or advanced age.

Percutaneous methods for treating mitral regurgitation, which have been described only recently, have the potential to offer a less invasive alternative to patients who are good surgical candidates, and to create therapy options for high-risk patients where none exist today. Previously, percutaneous therapy for valvular heart disease was limited to balloon valvuloplasty for pulmonic, aortic, and mitral valve stenosis.<sup>1–7</sup>

However, a variety of advances have recently facilitated development of methods to treat mitral regurgitation using catheter techniques via the percutaneous route. Most of these approaches are modifications of established surgical therapies. The mainstay of surgical

repair for mitral regurgitation has been annuloplasty. Rings that encircle the mitral annulus to varying degrees have been used with great success for many years. An important feature of many of these devices is that they do not necessarily capture the entire circumference of the mitral annulus.

#### Annular Approaches

Recognition that the coronary sinus (CS) parallels the mitral annulus has led to a percutaneous approach.<sup>8,9</sup> A device may be passed via the CS toward the great cardiac vein and thus encircle about 2/3–3/4 of the circumference of the mitral annulus in a manner analogous to surgical annuloplasty rings. The potential to reach around enough of the circumference of the CS to achieve a reduction in mitral regurgitation is the key element for this approach (Fig. 1). A variety of devices, delivered via a transvenous jugular approach, can be placed into the CS. Tension placed on the CS results in a decrease in mitral annular circumference. In animal models, this has resulted in significant, sustained improvements in mitral regurgitation.<sup>10</sup>

Intraoperative testing of some of these CS implants has been performed on a temporary basis without permanent device implantation.<sup>11,12</sup> Patients taken for surgical mitral annuloplasty have had a percutaneous device placed while on the operating table. The de-

---

Address for reprint: Ted Feldman, M.D., Evanston Hospital, 2650 Ridge Ave., Evanston, IL 60201. E-mail: tfeldman@enh.org

## CATHETER-BASED MITRAL VALVE REPAIR THERAPIES



**Figure 1.** Annuloplasty via the coronary sinus (CS). In the left panel a guide catheter has been passed from the right atrium into the CS, to allow delivery of a device in the anterior interventricular vein or proximal CS. Note that the mitral leaflets do not coapt adequately. The middle panel shows a cardiac dimensions annuloplasty device partially deployed. On the right, the device has been deployed and tensioned, and the guide catheter has been removed. The mitral leaflets now coapt as a result of tension placed on the valve to compress the septal-to-lateral dimension.

degree of reduction in mitral regurgitation can thus be evaluated, after which the device can be removed and the planned surgical procedure completed. Preliminary work with two devices has shown improvements in mitral regurgitation, but not yet of a degree sufficient to consider using these devices for permanent implantation.

Meanwhile, preliminary work in autopsy specimens and with limited temporary implantation in small numbers of patients has shown that the relationship of the CS to the mitral annulus in patients is highly variable compared to what has been observed in preclinical models. In addition, branches of the circumflex coronary artery may cross over or under the CS. Both of these factors are challenges to the development of mitral annuloplasty devices placed via this route.

The first permanent human implants of a CS annuloplasty device were reported by Webb et al.<sup>13</sup> The device uses two stents with a contractile connecting bridge between them to diminish the mitral annular circumference. Among five treated patients, the bridge fractured in three without any clinical complications but with loss of efficacy. This has led to a redesign of the device and resumption of the trial. It is clear that many problems will have to be solved before these technologies are ready for wide use.

**Alternative Annular Approaches.** Another approach to mitral annuloplasty that eliminates some of the challenges posed by the CS involves direct access to the left ventricle with placement of a device on the ventricular side of the mitral annulus. Access to the small space underneath the mitral leaflets via retrograde aortic catheterization is technically difficult, but may be achieved using deflectable catheters. Anchoring of an annuloplasty device to the ventricular surface of the an-

nulus via this route has been accomplished successfully in animal models.

A newer, completely novel approach to treating mitral regurgitation is the transpericardial route.<sup>14</sup> Pads can be anchored on the epicardial surface with a tensioning cable used to pull them together. This results in papillary muscle reorientation and less distortion of the left ventricular geometry caused by ventricular chamber dilatation. Diminution of the septal-to-lateral dimension of the mitral annulus can be accomplished using a transpericardial delivery system with epicardial tensioning devices. Decreasing the septal-lateral dimension moves the posterior leaflet toward the septum, resulting in improved coaptation with the anterior leaflet.

### Leaflet Repair

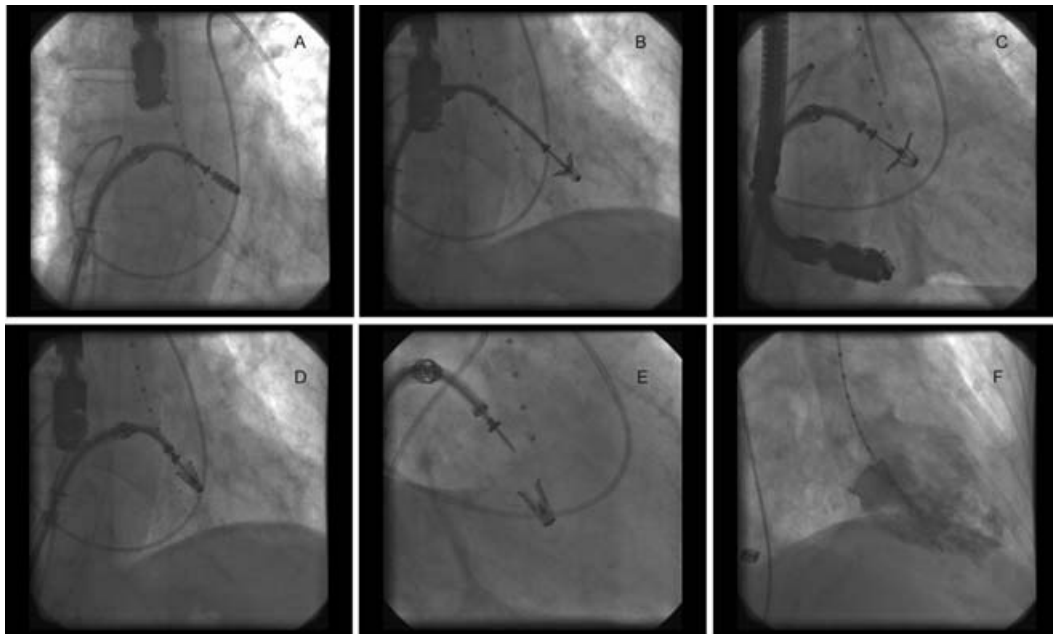
Direct leaflet repair has also been accomplished percutaneously. One type of surgical leaflet repair involving plication of the free edges of the anterior mitral leaflets to one another was developed by Otavio Alfieri in the early 1990s.<sup>15,16</sup> Suturing together the free edges of the central segments of the leaflets was initially used by Alfieri for patients suffering from mitral prolapse, frequently bileaflet prolapse which could not be managed with other repair techniques. Plication of the leaflets results in a double or “bow-tie” orifice, which reduces the orifice area and also insures coaptation of the prolapsing segment. Alfieri and his colleagues have subsequently gone on to demonstrate that this technique can also be used successfully in patients suffering from functional mitral regurgitation. A method to achieve plication of the mitral leaflets and create a double-orifice valve in this manner has been

adapted for percutaneous use.<sup>17</sup> Via a transseptal guiding catheter, a metal clip can be navigated through the left atrium and into the mitral orifice, and then deployed on the mitral leaflets. This approach has been tested in an animal model and shown to yield similar results to the procedure used in patients. A tissue bridge forms over the clip after a few months in the same manner as seen after suturing of the leaflets in patients.<sup>18</sup>

The percutaneous procedure is accomplished in patients using a 24Fr transseptal guide catheter. After standard transseptal puncture, the guide catheter is placed in the mid left atrium. The mitral clip is delivered using a catheter with a multi-axial steering apparatus so that it can be maneuvered into the center of the mitral orifice in three dimensions. Central placement of the device is critical, as is orienting it with the clip arms perpendicular to the line of mitral leaflet coaptation. The procedure is guided by a combination of fluoroscopic and echocardiographic imaging and requires transesophageal echocardiography (Fig. 2). Clip

placement, along with evaluation of the newly formed double orifice and reduction in mitral regurgitation, can be performed immediately. If the mitral regurgitation jet is seen to be lateral or medial to the clip, the clip can be opened, the leaflets released, the clip repositioned, and the mitral leaflets regrasped to improve results. In the event that adequate control of mitral regurgitation cannot be achieved, a second clip may be added, or the first clip may be opened and removed from the patient.

**Evalve/EVEREST-I.** A phase I clinical trial (EVEREST-I; the Evalve Cardiovascular Valve Repair System Endovascular Valve Edge-to-Edge Repair Study) has been reported.<sup>19</sup> Surgical candidates with moderate-severe or severe mitral regurgitation (grade 3+ or 4+) with symptoms (or asymptomatic with ejection fraction [EF] <60% or left ventricular end systolic dimension [LVESD] >45 mm) were included. Key exclusion criteria included EF <30%, LVESD >55 mm, endocarditis, previous sternotomy, and rheumatic



**Figure 2.** A. The upper left panel shows the guide catheter positioned in the mid left atrium. The clip delivery system has been maneuvered to position the clip within the left atrium, directly over the mitral valve line of coaptation. A transesophageal probe is seen at 12 o'clock. There is a pulmonary artery catheter looped in the right atrium, and a marker pigtail positioned in the mid left ventricular cavity. B. The clip has been opened and passed across the mitral leaflet into the left ventricle. C. The open clip arms have been pulled back to capture the moving mitral valve leaflets. D. As soon as transesophageal echo verifies that the leaflets have been captured in the clip arms, the clip arms are closed as shown here. E. The clip has been detached from the clip delivery system. F. A diastolic frame taken during left ventriculography demonstrates the position of the clip attached to the mitral leaflets.

heart disease. The procedure uses general anesthesia, fluoroscopy, and echocardiographic guidance. A 24Fr guide catheter is positioned in the left atrium. The clip is centered over the mitral orifice, passed into the left ventricle, and pulled back to grasp the mitral leaflets. After verification that the mitral regurgitation is reduced, the clip is released.

Six-month follow-up on 27 patients has been reported.<sup>19</sup> Clips were implanted in 88% of patients. There were no procedural complications and four major adverse events at 30 days: partial clip detachment in three patients, who underwent elective valve surgery; and postprocedure stroke in one patient, which resolved at 1 month. Three additional patients had surgery for unresolved mitral regurgitation, leaving 18 patients free from surgery. In 13 of the 14 patients with reduction of mitral regurgitation to  $\leq 2+$  after 1 month, the reduction was maintained at 6 months. Patients who required subsequent surgery had elective mitral valve repair or intended replacement.

In the event that a clip is not ultimately placed, mitral valve surgery can be undertaken electively without losing the options for either surgical repair or mitral valve replacement. Even when a clip is placed, subsequent surgical repair has been possible as much as 18 months later. To date, the procedure has been accomplished safely and a significant reduction in mitral regurgitation has been achieved in the majority of patients treated. The average length of hospital stay is  $<2$  nights. Management of the femoral venous puncture has not been any more challenging than for other valvular interventional therapies via the transseptal route. Further study is necessary to define the role of this therapy relative to mitral valve repair using surgical methods. The ideal patient population for this procedure will be defined by ongoing trial experience.

In the EVEREST phase I trial there was a referral bias for elderly patients who were poor candidates for mitral valve surgery. This is reflected by the median age (71 years) in EVEREST compared to patients undergoing repair in the Society of Thoracic Surgeons database (59 years). It is intuitive that percutaneous therapies would be desirable for high-risk patients.

**EVEREST II.** The EVEREST phase II randomized trial is a comparison with surgical valve repair or valve replacement. A number of factors are interesting about this trial design. There are no prospective, core lab-evaluated, intention-to-treat trials of mitral repair or replacement therapy in the surgical literature. Thus, the proportion of patients for whom repair is intended,

but in whom replacement is ultimately performed, is not clearly defined. Also, the results of mitral repair in terms of the degree of reduction of mitral regurgitation have never been assessed using objective criteria for mitral regurgitation grading and a core laboratory.<sup>20</sup> The randomized EVEREST phase II trial will be groundbreaking not only in the development of the percutaneous therapy, but also in defining the contemporary results of mitral valve surgery. Determining the specific population for this technology, whether it be elderly patients who are at high risk for surgical therapy or younger patients with severe, yet asymptomatic, mitral insufficiency, will require extensive investigative trials and clinical experience.

Understanding among cardiology practitioners of the mitral valve pathoanatomy and the specific methods needed to repair different pathologies is clearly important. Therapy for dilated cardiomyopathy with functional mitral regurgitation, ischemic mitral regurgitation, and mitral valve prolapse will all likely be different.<sup>21</sup> Development of these new catheter-based technologies will benefit from the input of the various interventional, surgical, and imaging cardiovascular specialties. We are on the threshold of an exciting era in catheter therapy for valvular heart disease. Percutaneous valve repair and replacement are realities in clinical research, and likely soon in clinical practice. These approaches are already attractive for use in older patients, and will hopefully make treatments available to many with no current options while making procedures less invasive for still others.

---

*Acknowledgment:* Dr. Feldman is the Principal Investigator for the EVEREST trial.

---

## References

1. Bonow RO, Carabello B, De Leon AC Jr, et al. Guidelines for the management of patients with valvular heart disease: Executive summary. A report of the American College of Cardiology/American Heart Association Task Force on Practice Guidelines (Committee on Management of Patients with Valvular Heart Disease). *Circulation* 1998;98:1949-1984.
2. Feldman T, Chiu YC, Carroll JD. Catheter balloon dilatation for discrete subaortic stenosis in the adult. *Am J Cardiol* 1987;60:403-405.
3. Inoue K, Owaki T, Nakamura T, et al. Clinical application of transvenous mitral commissurotomy by a new balloon catheter. *J Thorac Cardiovasc Surg* 1984;87:394-402.
4. Feldman T, Herrmann HC, Inoue K. The technique of percutaneous transvenous mitral commissurotomy using the Inoue

- balloon catheter. *Cathet Cardiovasc Diagn* 1994;2(Suppl.):26–34.
5. Feldman T. Hemodynamic results, clinical outcome and complications of Inoue balloon mitral valvotomy. *Cathet Cardiovasc Diagn* 1994;2(Suppl.):2–7.
  6. Otto CM, Mickel MC, Kennedy JW, et al. Three year outcome after balloon aortic valvuloplasty. Insights into prognosis of valvular aortic stenosis. *Circulation* 1994;89:642–650.
  7. Sakata Y, Sayed Y, Salinger MH, et al. Percutaneous balloon aortic valvuloplasty: Antegrade transseptal vs. conventional retrograde transarterial approach. *Catheter Cardiovasc Interven* 2005;64:314–321.
  8. Maniu CV, Patel JB, Reuter DG, et al. Acute and chronic reduction of functional mitral regurgitation in experimental heart failure by percutaneous mitral annuloplasty. *J Am Coll Cardiol* 2004;44:1652–1661.
  9. Byrne MJ, Kaye DM, Mathis M, et al. Percutaneous mitral annular reduction provides continued benefit in an ovine model of dilated cardiomyopathy. *Circulation* 2004;110:3088–3092.
  10. Byrne MJ, Power JM, Alferness CA, et al. Percutaneous mitral annular reduction: A novel approach to the management of heart failure associated mitral regurgitation. *Circulation* 2003;108:IV-444.
  11. Liddicaot JR, Mac Neill BD, Gillinov AM, et al. Percutaneous mitral valve repair: A feasibility study in an ovine model of acute ischemic mitral regurgitation. *Catheter Cardiovasc Interven* 2003;60:410–416.
  12. Oesterle SN, Gillinov AM, Chin CH, et al. Percutaneous catheter-based mitral valve repair. *J Am Coll Cardiol* 2002;39:432A. Abstract.
  13. Webb JG, Harnek J, Munt BI, et al. Percutaneous transvenous mitral annuloplasty; initial human experience with device implantation in the coronary sinus. *Circulation* 2006;113:851–855.
  14. Grossi EA, Saunders PC, Woo J, et al. Intraoperative effects of the coapsys annuloplasty system in a randomized evaluation (RESTOR-MV) of functional ischemic mitral regurgitation. *Ann Thorac Surg* 2005;80:1706–1711.
  15. Alfieri O, Elefteriades JA, Chapolini RJ, et al. Novel suture device for beating-heart mitral leaflet approximation. *Ann Thorac Surg* 2002;74:1488–1493.
  16. Alfieri O, Maisano F, DeBonis M, et al. The edge-to-edge technique in mitral valve repair: A simple solution for complex problems. *J Thorac Cardiovasc Surg* 2001;122:674–681.
  17. St. Goar FG, James FI, Komtebedde J, et al. Endovascular edge-to-edge mitral valve repair: Short-term results in a porcine model. *Circulation* 2003;108:1990–1993.
  18. Fann JI, St. Goar FG, Komtebedde J, et al. Off-pump edge-to-edge mitral valve technique using a mechanical clip in a chronic model. *Circulation* 2003;108:IV-493–IV-494.
  19. Feldman T, Wasserman HS, Herrmann HC, et al. Percutaneous mitral valve repair using the edge-to-edge technique: 6 month results of the EVEREST phase I clinical trial. *J Am Coll Cardiol* 2005;46:2134–2140.
  20. Zoghbi WA, Enriquez-Sarano M, Foster E, et al. American Society of Echocardiography. Recommendations for evaluation of the severity of native valvular regurgitation with two-dimensional and Doppler echocardiography. *J Am Soc Echocardiogr* 2003;16:777–802.
  21. Feldman T. Percutaneous valve repair and replacement: Challenges encountered, challenges met, challenges ahead. *Circulation* 2006;113:771–773.